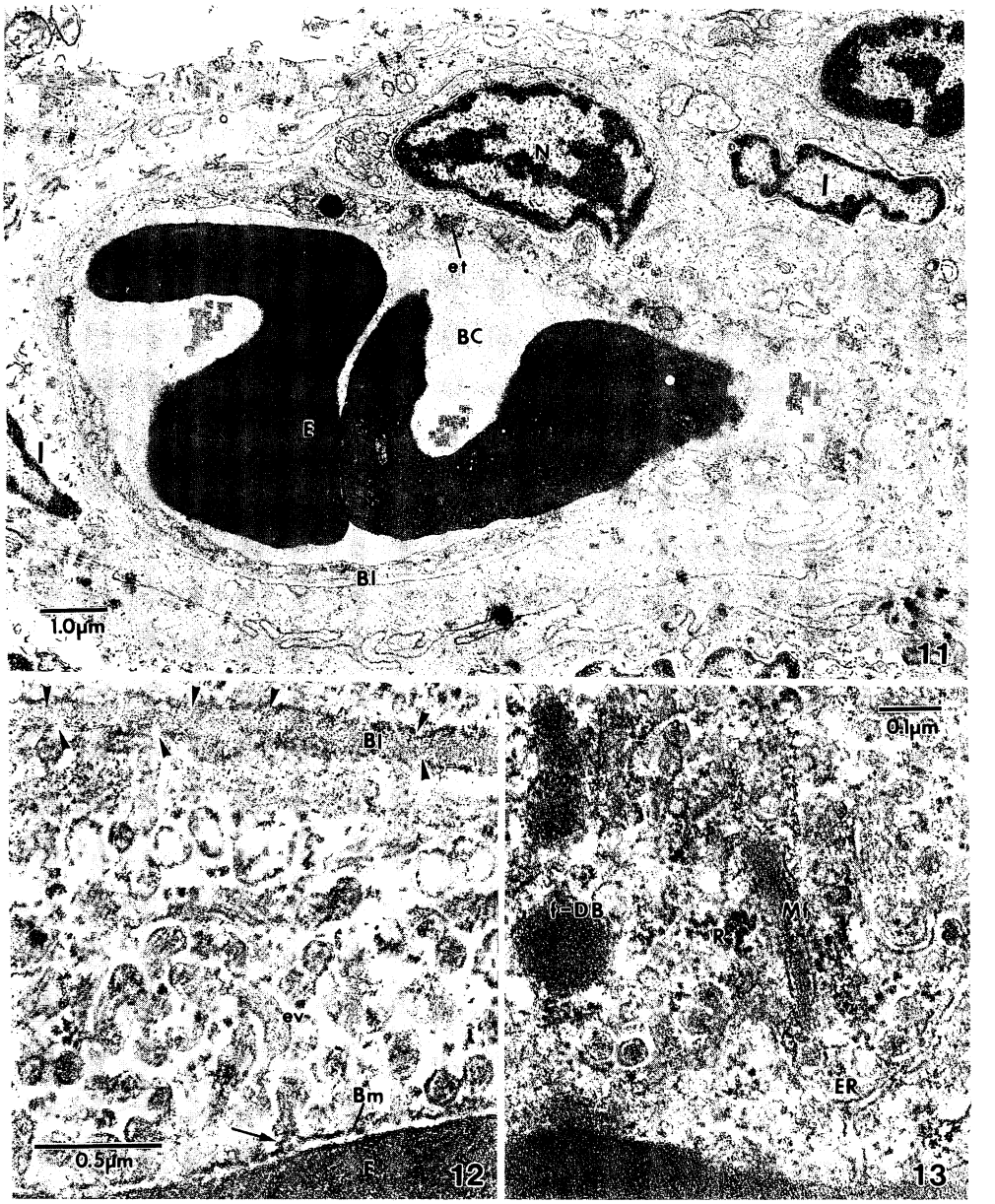

Fig. 11. Nucleated erythrocytes (E) are clearly seen in the intraepithelial blood capillary (BC), which is reinforced with young Type I cells (I). Bl, basement lamina; et, endothelium; N, nucleus of endothelium.

Figs. 12, 13. Endothelium of blood capillary. Endocytosis or exocytosis (arrow) is seen in the basement membrane (Bm), just adjacent to the blood capillary space, and a number of endothelial filtration pores (arrow heads) are also apparent in the basement lamina (Bl). E, nucleated erythrocyte; ER, endoplasmic reticula; ev, endoplasmic vesicle; f-DB, fibrous dense body; Mf, lamellar structure of microfilament; R, free ribosome.

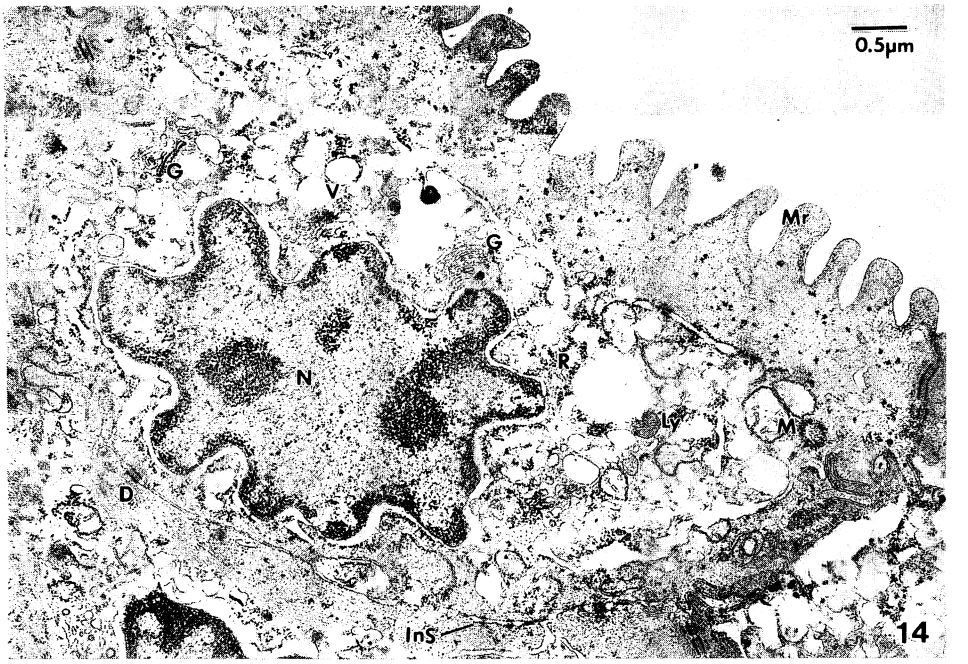

Fig. 14. Type I cell during its senescent phase. D, desmosome; G, Golgi apparatus; InS, intercellular space; Ly, lysosomal dense body; M, mitochondrion; Mr, microridge; R, free ribosome; V, vacuole.

Fig. 15. Type I cell dropping off. Abbreviations are the same as in Fig. 14.

blood capillaries (Fig. 10). Tight junctions are present in the terminal web, and complicated interdigitations are also seen in the adjacent cells (Figs. 3 and 4). Type I cells usually occur in the senescent phase, with young Type I cells always located just beneath the senescent cells. The blood capillaries are also reinforced with young Type I cells. A few nucleated erythrocytes are distributed in the lumen of the blood capillaries (Figs. 10 and 11). A considerable number of endothelial filtration pores are

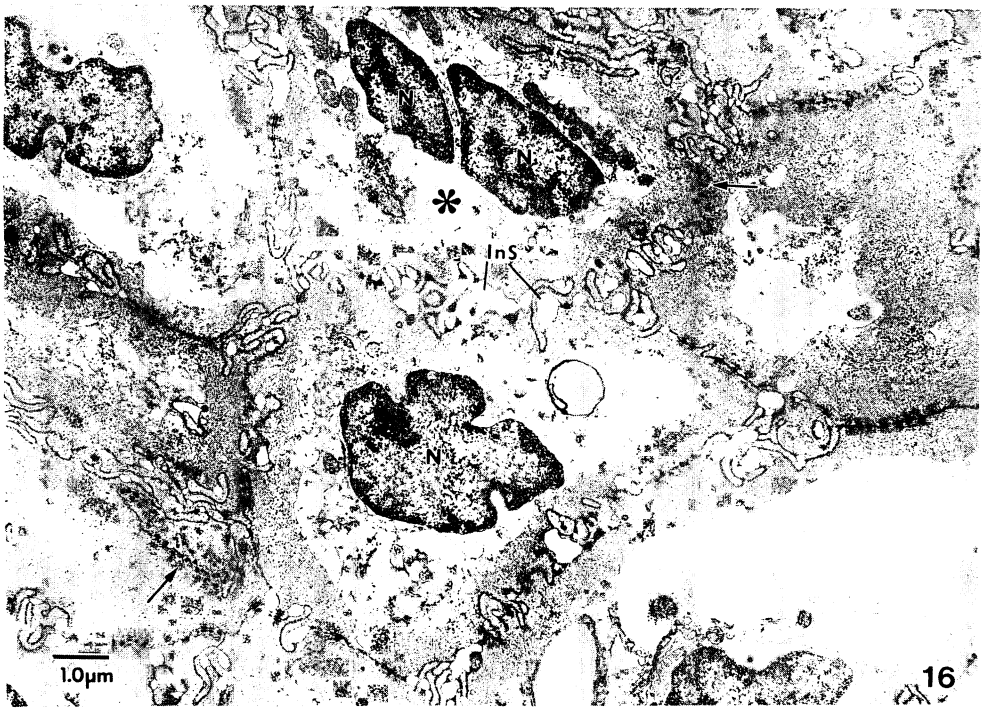

Fig. 16. Fusion found in Type I cell. Numerous intercellular spaces (InS) between the plasma membranes of the adjacent cells are formed, and a considerable number of dense, fibrous bodies (arrow) occur near the plasma membranes. N, nucleus. Asterisk indicates cells joined to each other.

observed in the basement lamina, ca. 0.1 μm in thickness, and either endocytosis or exocytosis is detected in the basement membrane just adjacent to the blood capillary space (Fig. 12). Numerous endoplasmic vesicles associated with free ribosomes, a few endoplasmic reticula, lamellate microfilaments and fibrous dense bodies are also found in the endothelium of the blood capillary (Figs. 12 and 13). During the senescent phase of Type I cells, the nucleus becomes contracted, and a few prominent Golgi apparatus, lysosome-like bodies and large vacuoles occur in the cytoplasm. A few desmosomes and intercellular spaces are also found in the plasma membranes of the adjacent cells, where no interdigitations are seen (Fig. 14). During the last phase of Type I cells, the cytoplasm is poor in cell organelles, containing only a few mitochondria, with wide intercellular spaces being formed between the plasma membranes of the adjacent cells. The senescent cells then fall off completely (Fig. 15).

The middle layer of the epidermis contains several strata of Type II cells. This cell type is characterized by having an enormous vacuole in the cytoplasm, the vacuole becoming larger due to fusion of the plasma membranes of adjacent cells. During the process of fusion, numerous, wide, intercellular spaces are formed between the plasma membranes of adjacent cells, and a considerable number of dense, fibrous bodies are collected around the lamellated cisternae of the endoplasmic reticula (Figs. 16 and 17). Cell organelles, such as mitochondria, dense, lysosome-like bodies, free ribosomes and numerous microfilaments which have collected around the fibrous dense bodies, are obvious (Fig. 17). Well-developed endoplasmic reticula fuse to form a lamellar structure separating the septate desmosomes (Fig. 18).

The basal layer comprises a stratum of filament-containing cells, generally long and ovoid or spindle-shape. The basal cell has a large, centrally located nucleus and few mitochondria, endoplasmic reticula and Golgi apparatus. This cell is similar to both Type I and Type II cells, having numerous microfilaments (Fig. 19), which are assembled near the apical region of the rough basement lamina and the filaments connected with the basement lamina. Endocytosis is recognized in the lamina, and endo-

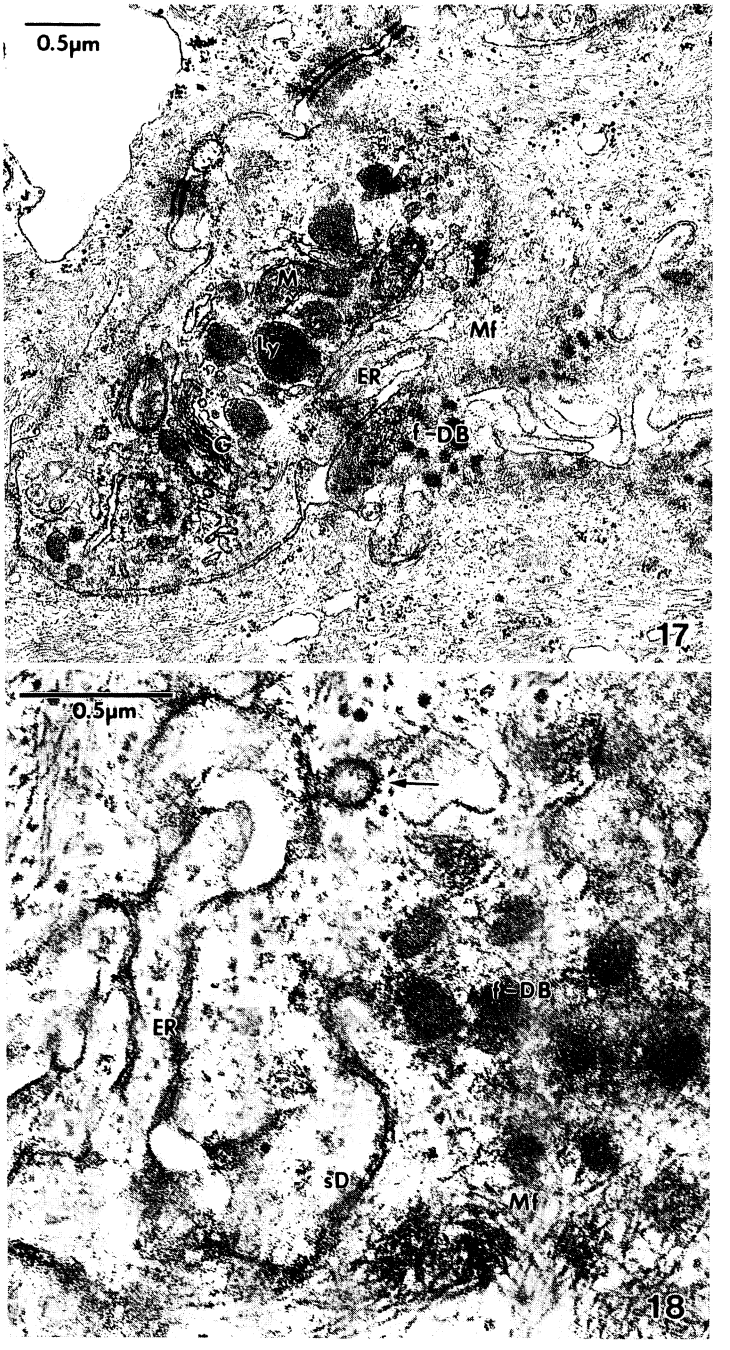

Figs. 17, 18. Cytoarchitectures found in the process of fusion. A number of fibrous dense bodies (f-DB) gather around the lamellar endoplasmic reticula (ER) associated with a coated vesicle (arrow) and septate desmosome (sD). G, Golgi apparatus; Ly, lysosomal dense body; M, mitochondrion; Mf, microfilament.

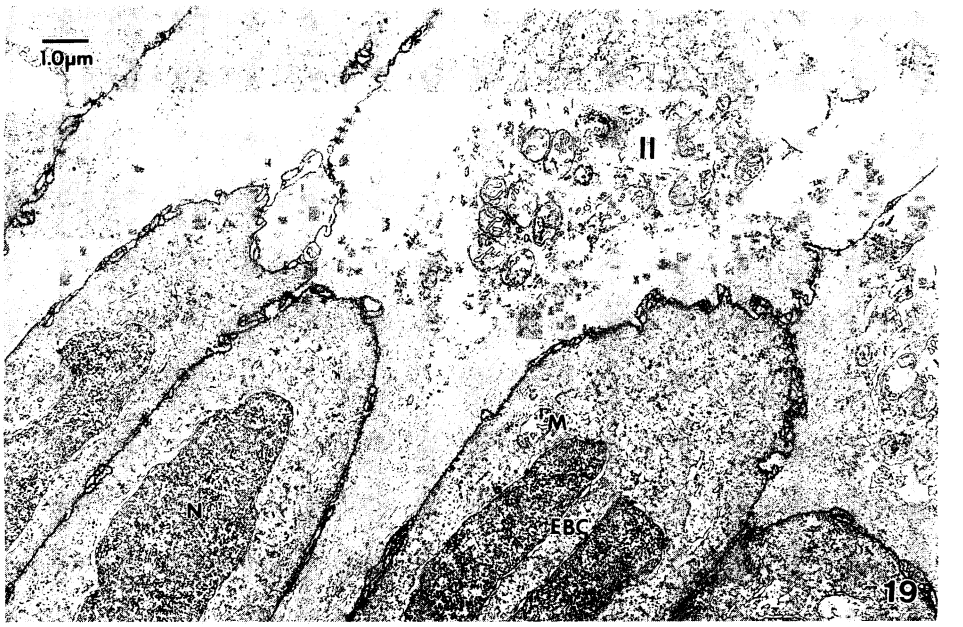

Fig. 19. Basal region of the epidermis. EBC, basal cell of the epidermis; M, mitochondrion; N, nucleus; II, Type II cell.

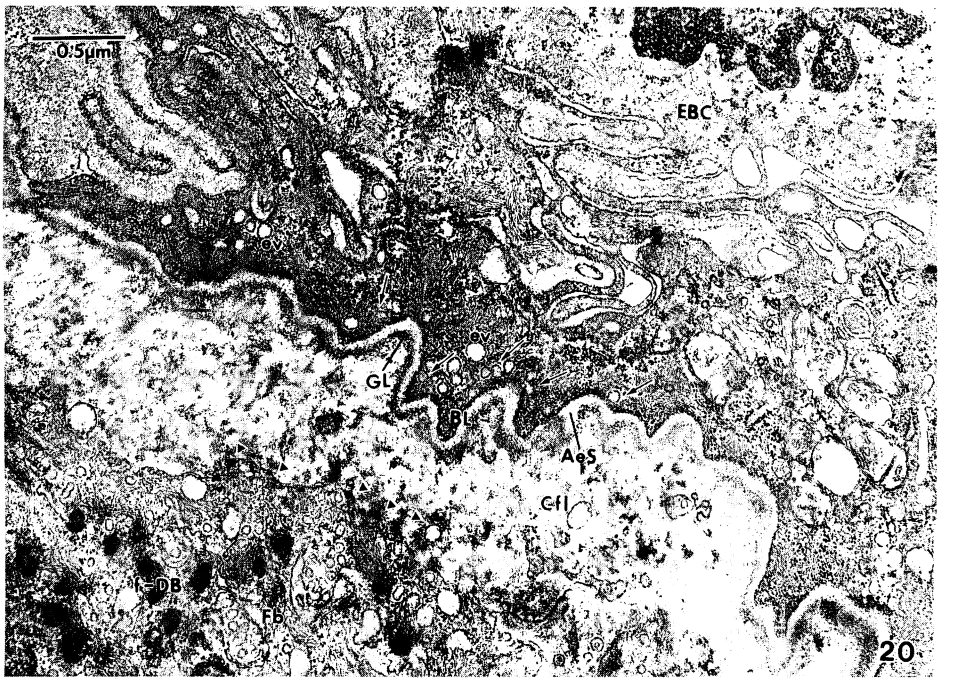

Fig. 20. Apical region of the dermis. Endocytosis (arrows) is detected in the basement lamina (BL), and some endoplasmic vesicles (ev) are also seen near the basement lamina. A fibroblast (Fb) is in the process of releasing a series of granular materials (arrow heads). AeS, adepidermal space; Cfl, collagenous lamella of the dermis; EBC, basal cell of the epidermis; f-DB, fibrous dense body; GL, granular layer.

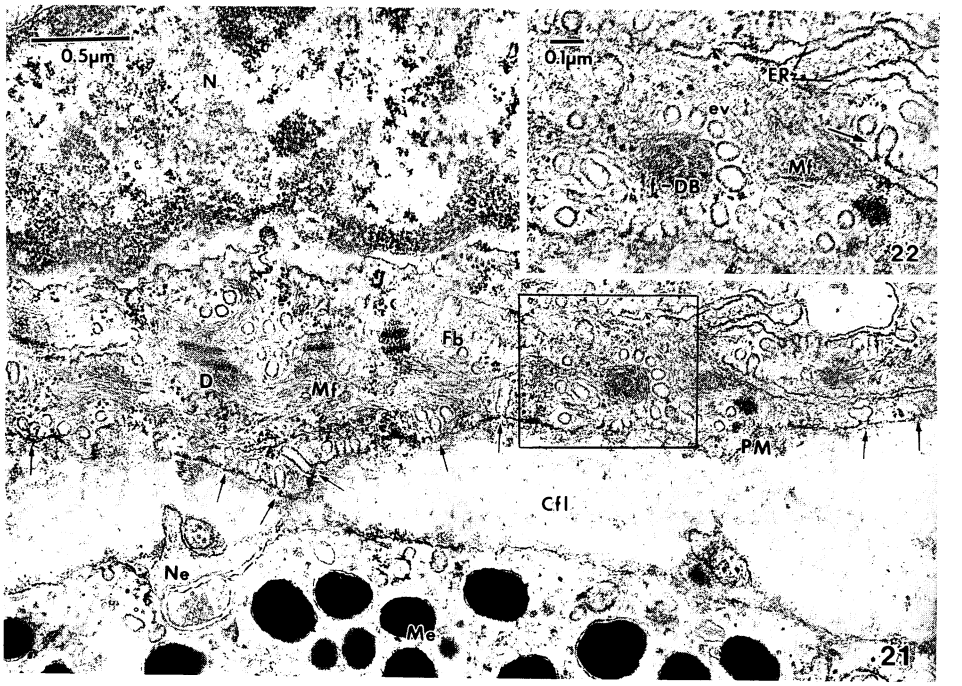

Fig. 21. Cytoarchitecture of the fibroblast (Fb). Vigorous exocytosis (arrows) are found in the plasma membrane (PM). Cfl, collagenous lamella of the dermis; D, desmosome; Me, melanophore; Mf, microfilament; N, nucleus; Ne, nerve ending.

Fig. 22. Enlargement of area in Fig. 21. Fibroblast includes lamellar endoplasmic reticula (ER) and coated endoplasmic vesicles (ev and arrow) in the cytoplasm. f-DB, fibrous dense body; Mf, microfilament.

plasmic vesicles are frequently found in the basal region (Fig. 20).

2) Dermis. The dermal layer consists of collagenous fibrils and a number of fibroblasts, and constitutes a thick band in the caudal portion. An adepidermal space is lined-up along the basement lamina, with an underlying mass of fine filamentous or granular layer. The collagenous fibrils are located in close proximity to the lamina, such that some of the fibrils are attached to it. A considerable number of fibroblasts are usually found in the uppermost layer of the dermis. The fibroblasts, which release a series of granules consisting of collagenous fibrils (Fig. 20), contain a large number of filaments, ca. 7 nm in diameter (Figs. 21 and 23). During differentiation of the fibroblast, some electron-dense bodies derived from numerous microfilaments, a considerable number of cisternae associated with the endoplasmic reticula, coated endoplasmic vesicles and some desmosomes were found in the cytoplasm, and vigorous exocytosis was encountered in the plasma membrane (Figs. 21 and 22). At the perinuclear region of the fibroblast, the endoplasmic reticula are joined with each other forming a lamellate structure intervening a considerable number of desmosomes and septate desmosomes. Strong interdigitations occur in the region of free desmosomes. Fibrous bodies having moderate electron density and masses of free ribosomes were also seen in the perinuclear portion (Fig. 23). The nucleus is located near the apical region, and a number of intercellular spaces occur in the lamellar endoplasmic reticula where the fibroblasts change into senescent cells. Dense, lysosomal bodies are observed near the aforementiond spaces. Endocytosis or exocytosis is also recognized in the intracytoplasmic membranes consisting of endoplasmic reticula. Pinocytotic materials are also included in the intercellular spaces (Figs. 24 and 25). Bundles of collagen fibrils are arranged in several strata, with each stratum oriented at right angles. Many glycogen granules are distributed along each stratum (Fig. 26). Chromatophores comprising melanophores, as well as the endings of unmyelinated nerve bundles, are usually found in the apical